



PATIENT

Nala McDonald

SPECIES

Canine

BREED

English Bulldog

SEX

Female Spayed

AGE

9 years

WEIGHT

67lbs

INTERPRETED BY

Maggie Machen
Lamy, DVM, DACVIM
(Cardiology)

HOSPITAL NAME

Veterinary Housecall
Services

REFERRING VET

Dr. Golden

INVOICE

21336

DATE

10/4/21

PRESENTING CLINICAL SIGNS

History: Increased Panting. SC MCT on left thigh first noted 4/2021 is getting larger. Her appetite has become more selective, yet she is gaining weight. She is panting more. No pu/pd/v/d/c/s noted. She is now walking with a "wobble". Diet: RC Satiety support Wt. mgmt. Exam: Wt. 67.6lbs, BCS-8/9. HR-140-160bpm, RR-Panting. BAR. Aggressive with owner but did fine in exam room without muzzle. EENT: Mild tear staining OS>OD otherwise NSF. Oral: #304 crown fractured at gum line and other teeth severely worn. H/L: HR-140-160bpm possible 2/6 L systolic HM noted. RR-Panting, referred upper airway sounds. Abd: Tense, but not painful and no obvious mass effect noted. Rectal: WNL. LN: WNL. Integ: SC MCT on lateral left thigh now 3cm x 2cm (increased from 1cm in April). Left metatarsal pink dermal skin tag ~ 2mm. Probable small adenomas on ventral tail. M/S/N: Stifles swollen, suspect right drawer and left as well. Assessment: Dental disease with fractured #304, Probable bilateral CCL injuries. SC MCT Left thigh. Skin tag. Plan: CBC/Chemistry/T4 -----> Idexx. proBNP ----> Idexx. Will consider surgical removal of MCT and other masses pending BW results.
-Pertinent abnormal PE/Chem/CBC/UA Results: (9-21-21) ProBNP 1119 (0-900), GLU 119, SDMA 11, CR 1.6, BUN 39. (4-17-21): GLU 128, SDMA 10, CR 1.5, BUN 32. (2-10-20): GLU 115, CR 1.2, BUN 20.
-Current medications: Previcox 227mg: 1/2 tab once daily. Gabapentin 300mg q 12 hrs. Movoflex 40-80: 1 chew once daily. ST once a month.
-Blood pressure: 130-150mmHg with doppler.
-Sedation used: Not needed.
-STAT: Not requested.

ECHOCARDIOGRAM FINDINGS

2D, m-mode, color flow and doppler imaging is available. Minimal diffuse thickening of mitral valve leaflets with no obvious prolapse into the left atrial lumen. No mitral regurgitation is identified. Normal left atrial dimension. Normal LV diameter with adequate myocardial function. The tricuspid valve appears subjectively normal, with no tricuspid regurgitation. The right heart is normal (subjective). No overt evidence of pulmonary arterial hypertension. The pulmonic and aortic valves are normal in morphology and mobility. No aortic abnormalities identified, however the LVOT velocity is mildly elevated. Normal pulmonic outflow velocities. No aortic or pulmonic insufficiency. No pericardial or pleural effusion noted. No cardiac tumors observed.

CARDIAC CHART

CANINE CARDIAC PARAMETERS	MR VMAX (m/s)	TR VMAX (m/s)	LA/AO (Boon method)	LA/AO (Heart Base; Swe)	FS (%)	EF (%)	EPSS (cm)
NORMAL PARAMETER	4.5-5.5	<2.7	1.3	<1.6	28-40	40-100	<0.6
PATIENT	NA	NA	NM	1.3	55	86	NM
CANINE CARDIAC PARAMETERS	HR (BPM)	AV VMAX (m/s)	PV MAX (m/s)	BODY WEIGHT (kg)	LA 2D short axis Base view (cm)	LVIDd Avg; 2D and m-mode short axis (cm)	LVIDs Avg; 2D and m-mode short axis (cm)
NORMAL PARAMETER	50-100	0.7-1.7	0.7-1.6	BELOW	BELOW	BELOW	BELOW
PATIENT	200	2.1	1.6	30.4	2.7	4.0	1.8
*Normal chamber parameters expressed as a mean value (SD)				3	1.27 (5.3)	2.46 (2.46)	1.36 (5.5)
BODY WEIGHT DEPENDENT PARAMETERS				5	1.40 (4.5)	2.74 (5.2)	1.60 (4.7)
<i>*Note: All measurements based upon multi-modal images and methods. An average value is reported.</i>				10	1.50 (3.8)	3.27 (3.5)	2.06 (3.1)
				15	1.83 (2.0)	3.71 (2.4)	2.43 (2.1)
				20	2.02 (1.9)	4.14 (2.2)	2.80 (2.0)
				25	2.18 (2.4)	4.48 (2.9)	3.10 (2.5)
				30	2.33 (3.3)	4.83 (3.9)	3.39 (3.4)
				35	2.48 (4.3)	5.17 (5.0)	3.69 (4.5)
				40	2.62 (5.2)	5.48 (6.1)	3.96 (5.4)
				50	2.88 (7.1)	6.07 (8.3)	4.46 (7.4)

Adapted from June Boon, Veterinary Echocardiography, 1998
Rishniw M and Hollis NE, J Vet Intern Med 2000; 14:429-435
Hansson et al, Vet Rad and Ultrasound 2002
Bonagura et al. Echocardiography: principles of interpretation, Vet Clin North Am 15:1177, 1995

INTERPRETATION OF THE FINDINGS & FURTHER RECOMMENDATIONS

The only cause of a murmur identified is increased flow velocity through the LVOT/aortic root. No obvious subaortic ridge or valvular abnormalities are visualized, and in the absence of structural abnormalities this is considered a benign flow murmur. If this is a new murmur, it is reasonable to monitor periodically via recheck echocardiography in the future. No significant valvular insufficiencies were noted, and no structural issues identified. No obvious cardiac or extra-cardiac masses are appreciated; however, it is important to note that small tumors are easily missed in the absence of effusion. Advanced imaging is recommended if suspicion is high. Finally, the heart rate is quite elevated throughout the study and a baseline ECG may be useful.

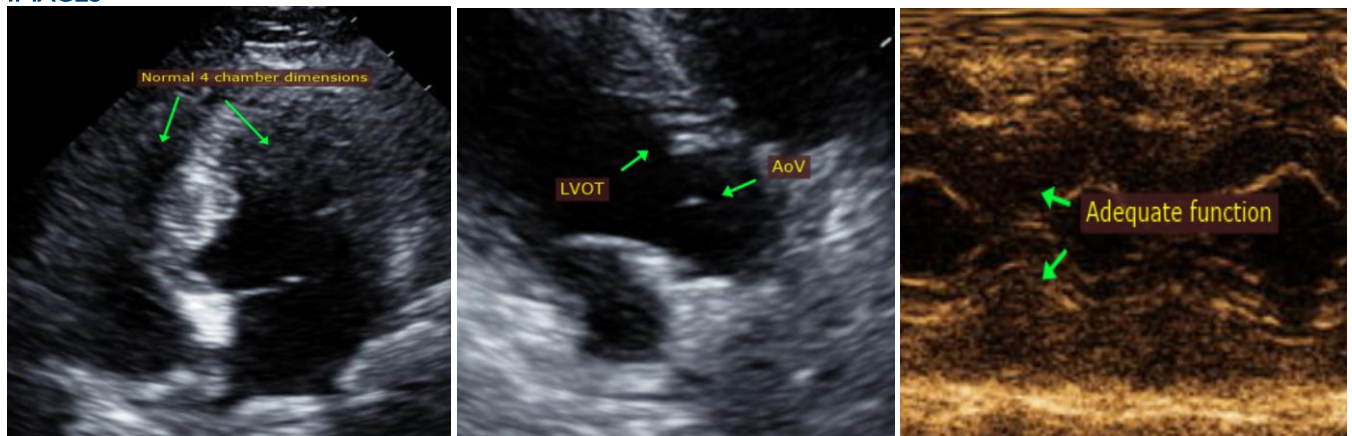
No obvious reason for NT-proBNP elevation is seen, most likely making this a false positive result (a known weakness of the test). Other possible causes should be considered, including hypertension. If no obvious cause is identified, reassessing this patient in 6-12 months is recommended to ensure early disease was not missed.

No cardiac medications are indicated. No cardiac contraindication for general anesthesia.

Monitor for any development of cough, labored breathing or exercise intolerance.

Recommend recheck echocardiogram in 12-18 months to screen for progression or development of concurrent cardiac disease that the preexisting murmur may mask.

IMAGES



The information and recommendations provided are based on the images presented by the referring veterinarian. No evaluation can be communicated regarding pathology that was not visible in the image/video clips provided.

Thank you for this referral. This report was generated using transcription software, and minor dictation errors may be present. If the clinical or image interpretation does not parallel your findings or if I can be of any further assistance, please contact me.

Maggie Machen Lamy, DVM
Diplomate of the American College of Veterinary Internal Medicine (Cardiology)
Email: info@sonopath.com